



ANTI-INFLAMMATORY ACTIVITY OF PHYCOCYANIN EXTRACT IN ACETIC ACID-INDUCED COLITIS IN RATS

RICARDO GONZÁLEZ*, SANDRA RODRÍGUEZ, CHEYLA ROMAY,
ODELSA ANCHETA, ADDYS GONZÁLEZ, JULIO ARMESTO,
DIADELIS REMIREZ and NELSON MERINO

Pharmacology Department, National Center for Scientific Research, PO Box 6990, Havana, Cuba

Accepted 22 September 1998

The anti-inflammatory effect of *c*-phycocyanin extract was studied in acetic acid-induced colitis in rats. Phycocyanin (150, 200 and 300 mg kg⁻¹ p.o.) was administered 30 min before induction of colitis with enema of 1 ml of 4% acetic acid per rat. Twenty-four hours later myeloperoxidase (MPO) activity was determined as well as histopathological and ultrastructural studies were carried out in colonic tissue. Phycocyanin substantially reduced MPO activity which was increased in the control colitis group. Also, histopathological and ultrastructural studies showed inhibition in inflammatory cell infiltration and reduction to some extent in colonic damage in rats treated with phycocyanin. The probable role of antioxidative and the scavenging properties of phycocyanin against reactive oxygen species in the anti-colitic effect is discussed in this paper. To our knowledge this is the first report on the anti-inflammatory effect of phycocyanin in an experimental model of colitis.

© 1999 The Italian Pharmacological Society

KEY WORDS: phycocyanin, anti-inflammatory, acetic acid, colitis, rat.

INTRODUCTION

Inflammatory bowel disease (IBD) is a chronic inflammatory disorder involving primarily the gastrointestinal tract and includes Crohn's Disease and ulcerative colitis [1].

The pathology of IBD is characterised by polymorphonuclear leukocyte (PMNL) infiltration, oedema, erythema, ulceration and lipid mediator release [1]. Although the etiology of IBD is unknown, currently there is consensus that metabolites of arachidonic acid such as leukotrienes and prostaglandins as well as reactive oxygen species (ROS) are involved in the induction and development of the disease [1–4]. Recently, we demonstrated that phycocyanin a biliprotein found in blue green algae such as *Spirulina* and *Arthrospira maxima* exerts scavenging action against ROS as well as

anti-inflammatory activity in various *in vitro* and *in vivo* experimental models [5]. Taking into account that these microalgae are used as nutritional supplements in many countries, it is conceivable that phycocyanin could be potentially used as a dietary supplement in IBD. Thus, in order to provide evidence in favour of this hypothesis we decided to test phycocyanin extract in acetic acid-induced colitis, an animal model that mimics some of the acute inflammatory responses seen in ulcerative colitis [1].

MATERIALS AND METHODS

Materials and animals

Male rats (Sprague–Dawley, 200–250 g) were purchased from the National Center for Laboratory Animal Production, Havana, Cuba. They were housed under a 12-h light–dark cycle with room temperature maintained at 23°C, humidity at 55% and food and water available *ad libitum*. The rats were fasted for 2 days prior to any intracolonic

* Corresponding author.

studies but were always allowed full access to water. The experiments were conducted in accordance with the ethical guidelines for investigations in laboratory animals and were approved by the Ethical Committee for Animal Experimentation of the National Center for Scientific Research.

All reagents not specifically described were purchased from Sigma (St. Louis, MO, USA).

Preparation of phycocyanin extract

Phycocyanin was extracted from the microalgae *Arthrospira maxima* as described in a Cuban patent [6]. The blue powder thus obtained showed a peak in the visible absorption spectrum of 617 nm, which is very close to the one reported for *c*-phycocyanin [7].

Induction of colitis and treatments

Groups of eight rats were used in the experiments. Phycocyanin (150, 200 and 300 mg kg⁻¹) and 5-aminosalicylic acid (5-ASA), at a dose of 200 mg kg⁻¹ used as reference drug, were administered by gavage to the rats. Water and 1% carboxymethylcellulose were used as vehicles of phycocyanin and 5-ASA, respectively. Thirty minutes later the rats, under light ether anaesthesia, received enemas of 1 ml of 4% acetic acid in water [8]. Twenty-four hours later, rats were killed by an overdose of ether, colons extirpated and divided for histological, ultrastructural and biochemical analysis. A group of non-treated rats was included in the experiments.

Determination of myeloperoxidase (MPO) activity

Colonic tissue was weighed and assessed for the content of MPO as previously described [9]. Briefly, tissue was minced and homogenised in 50 mM KH₂PO₄/K₂HPO₄ buffer (pH 6.0) containing 0.5% hexadecyltrimethyl-ammonium bromide (HTAB) in order to obtain 50 mg of tissue per millilitre. The homogenate was freeze-thawed three times to release the content of the neutrophils granules. After centrifugation, aliquots of the supernatant were taken for determination of MPO enzyme activity spectrophotometrically using hydrogen peroxide as substrate and *O*-dianisidine as the hydrogen donor. A unit of MPO activity was defined as that converting 1 μmol of hydrogen peroxide to water in 1 min at 22°C. MPO data are compiled as absorbance at 460 nm and reported as units per gram of tissue or reduction percent with respect to the control colitis group.

Histological assessment

Colonic samples were taken 2–4 cm proximal to the anus. Thereafter, the tissue was fixed in phosphate-buffered formaldehyde, embedded in paraffin and 5-μm sections were prepared. The tissue was stained with haematoxylin and eosin and evaluated by light microscopy, being scored in a blinded man-

ner by two expert pathologists. A histological grading scale was used for determination of the extent of inflammatory reaction in the tissue.

Each of the individual parameters estimated was graded 0–3 depending upon the severity of changes (0, no change; 1, mild; 2, moderate; 3, severe).

The evaluated parameters were: erosion, ulceration, mucosal necrosis, haemorrhage of mucosa, lamina propria and submucosal oedema and inflammatory cell infiltration. The severity of changes was subjectively graded and compared with controls.

Transmission electron microscopy

Colonic tissue from rats treated either with 4% acetic acid solution or with phycocyanin plus acetic acid were fixed in a cold solution of 3.2% glutaraldehyde in 0.1 M sodium cacodylate buffer. After 1 h, pieces of tissues were post-fixed in 2% osmium tetroxide, for an additional 1 h. Samples were dehydrated and finally embedded in Spurr resin. Ultrathin sections were stained with saturated uranyl acetate and lead citrate and observed in a JEM 100 S Electron microscope.

Statistical analysis

Statistical evaluation was by two-sample t-test after analysis of variance with significance ascribed when $P < 0.05$. All results are expressed as means ± SEM.

RESULTS

Effects of phycocyanin and 5-ASA on MPO activity and on damage scores in colitis induced by acetic acid in rats

Colitis induced by 4% acetic acid in rats resulted in significant increases in colonic MPO content with respect to normal control rats. However, the former effect was reversed in the group of rats with colitis which was previously treated with phycocyanin extract at doses of 150, 200 and 300 mg kg⁻¹ p.o. (Table I).

The greater inhibitory effect on MPO activity was achieved with the latter two doses, which indicates a reduction of neutrophil infiltration in colonic tissue. 5-ASA at a dose of 200 mg kg⁻¹ p.o, used as a drug reference, also substantially decreased MPO activity in rats with colitis (Table I).

In agreement with these findings, histological evaluation of colonic tissues revealed essentially normal mucosa in the non-treated control group, in contrast with mucosal haemorrhage, severe inflammatory cell infiltration, submucosal oedema and focal ulceration in acetic acid-treated rats (Fig. 1). In groups of rats pre-treated with phycocyanin (150, 200 and 300 mg kg⁻¹) there was only slight submucosal oedema, minimal subepithelial haemorrhage and mild inflammatory cell infiltration (Fig. 2). Thus,

Table I
Effects of phycocyanin and 5-ASA on MPO activity and on damage score in colitis induced by acetic acid in rats

Groups of rats	MPO activity (units/g tissue)	MPO inhibition (%)	Damage score (0-3)
Control normal	54.3 ± 2.18	-	-
Control colitis	290.7 ± 4.82	-	2.8 ± 0.2
Phycocyanin			
150 mg kg ⁻¹	128.6 ± 4.29*	55.7	2.0 ± 0.4*
200 mg kg ⁻¹	99.2 ± 3.72*	65.8	1.9 ± 0.4*
300 mg kg ⁻¹	99.0 ± 4.42*	65.9	1.6 ± 0.3*
5-ASA			
200 mg kg ⁻¹	81.3 ± 2.22*	72.0	1.4 ± 0.2*

* $P < 0.05$: Phycocyanin and 5-ASA groups *vs* control colitis group. There were eight rats in each group. Mean ± SEM are shown. Phycocyanin and 5-ASA were administered by gavage to rats. Enemas of 1 ml of 4% acetic acid in water were administered to rats in order to induce colitis.

the colonic damage score was reduced from 2.8 in the control colitis group to 1.6 in the group pre-treated with the greatest dose of phycocyanin.

Similar results were achieved with 5-ASA at a dose of 200 mg kg⁻¹ p.o (Table I), which also exerted protective effects on rat colonic mucosa that appears practically normal (Fig. 3).

Also, ultrastructural studies of colonic tissue provided evidence that phycocyanin administration resulted in reduced inflammation. Normal structure of the epithelial cells and basal area was observed in the colon of the non-treated control group [Fig. 4(A,B)]. However, in the colonic tissue of rats treated with 4% acetic acid was observed loss of microvilli,

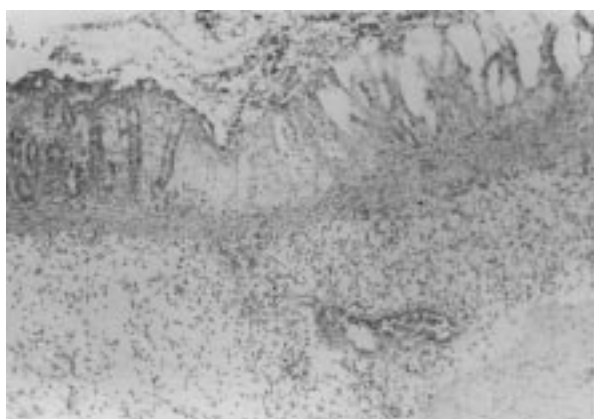


Fig. 1. Cross-section of rat colon obtained 24 h after exposure to acetic acid enema. Extensive transmucosal necrosis with remarkable inflammatory cell infiltration and submucosal oedema was observed (H&E; original magnification 100 ×).

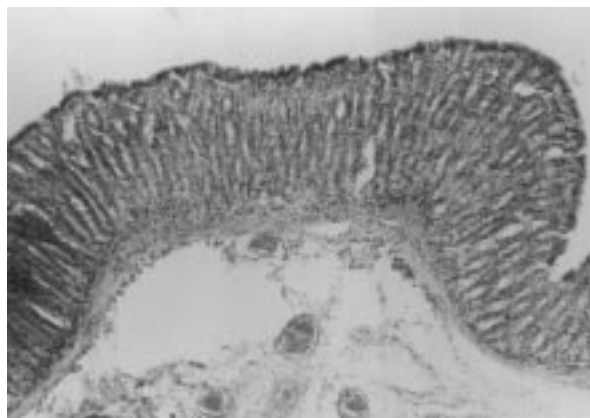


Fig. 2. Cross-section of rat colon in animal with induced colitis pretreated with phycocyanin (300 mg kg⁻¹ p.o.). Minimal damage of the mucosa with slight submucosal oedema and mild inflammatory cell infiltration (H&E; original magnification 100 ×).

swollen mitochondria with loss of cristae. Nuclear alteration such as dilation of the nuclear envelope was also observed [Fig. 5(A)]. In the basal area an extensive inflammatory infiltration with the presence of neutrophils was shown [Fig. 5(B)].

In rats with colitis pre-treated with phycocyanin at a dose of 300 mg kg⁻¹ p.o. was observed slight recovery of microvilli in some epithelial cells and in the basal area the inflammatory cell infiltration was almost absent (Fig. 6).

DISCUSSION

The most important finding of this study was that phycocyanin could reduce colitis induced by acetic acid in rats. To our knowledge it is the first report

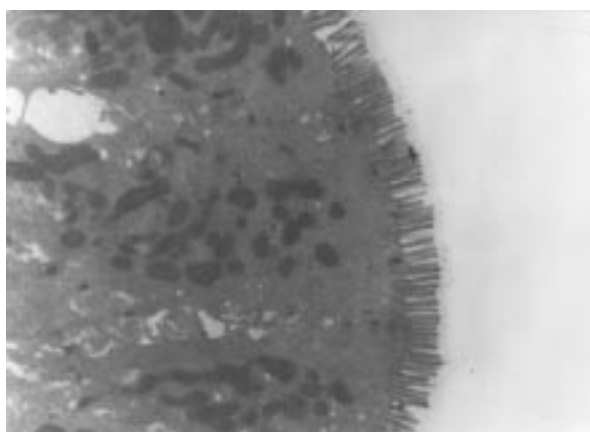


Fig. 3. Electron micrograph of colonic tissue of rat with colitis pretreated with 5-ASA (200 mg kg⁻¹ p.o.). Rat colonic mucosa shows remarkable recovery of damage (12,000 ×).

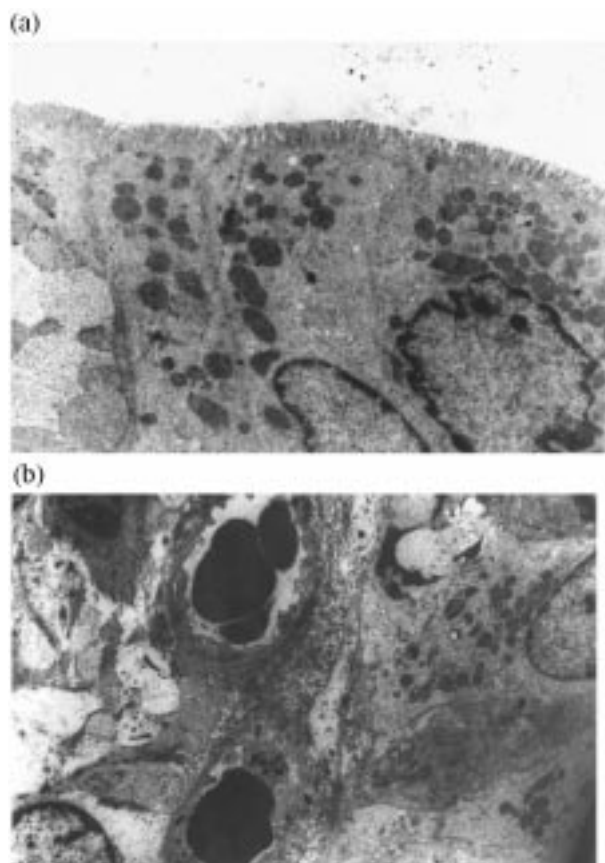


Fig. 4. Electron micrographs of colonic tissue of normal rat. Normal structure of the epithelial cells (A) and basal area (B) are observed (5200 \times).

on the anti-colitic effect of phycocyanin which was evident from the evaluation of histological features as well as ultrastructural analysis of colonic tissue and confirmed by measurements of MPO activity.

MPO is an enzyme present in neutrophils and at a much lower concentration in monocytes and macrophages. The level of MPO activity is directly proportional to the neutrophil concentration in the inflamed tissue [10]. Therefore measurements of MPO activity has been considered a quantitative and sensitive assay for acute intestinal inflammation [10].

Higa *et al.* [11] also demonstrated that changes of MPO activity in the colonic tissue of rats after induction of colitis paralleled well with the severity of mucosal damage. However, these authors using cyclophosphamide-treated neutropenic mice and treatment with a LTB_4 receptor antagonist ONO-4057 showed that neutrophils in the inflamed site but not those in blood circulation play an important role in the severity and the progression of mucosal damage in acetic acid-induced colitis [11].

In the present study a substantial reduction in neutrophil infiltration in colonic mucosal injury and MPO activity in animals with colitis treated with

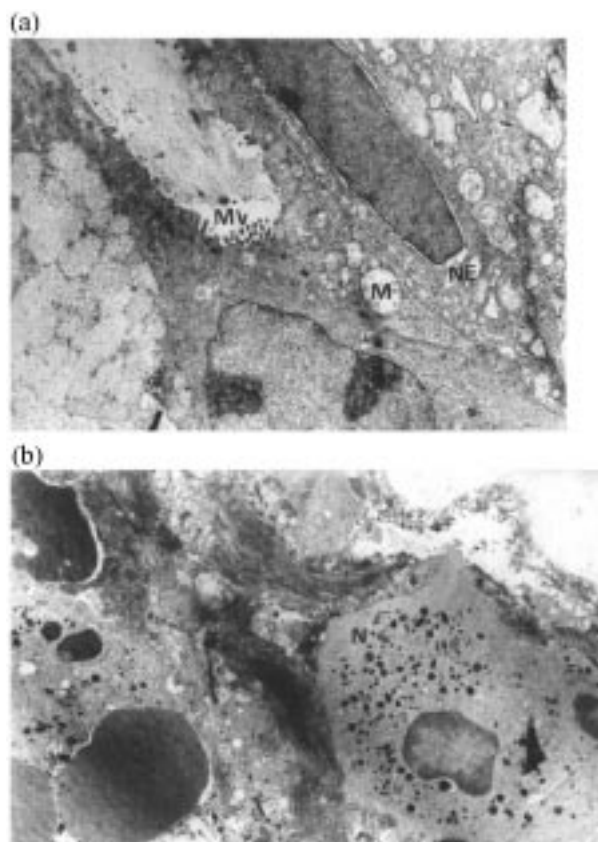


Fig. 5. Electron micrographs of rat colonic tissue in acetic acid-induced colitis at 24 h. (A) Epithelial cells with loss of microvilli (MV), swollen mitochondria (M) and nuclear envelope dilation (NE) are observed (6000 \times). (B) In the basal area, inflammatory cell infiltration, mainly neutrophils (N) are observed (6000 \times).

phycocyanin has also been found (Table I, Figs. 2 and 6), which support a beneficial effect of it.

Grisham *et al.* [2] and others [3, 4] have provided

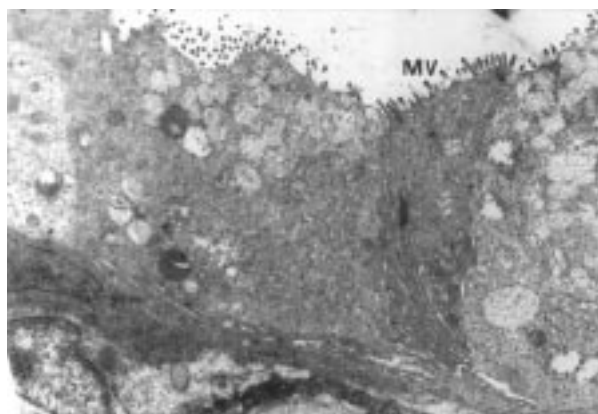


Fig. 6. Electron micrograph of colonic tissue of rat with colitis pretreated with phycocyanin (300 mg kg^{-1} p.o.). Slight recovery of microvilli (MV) some epithelial cells are observed. In the basal area it was not found in inflammatory cell infiltration (6000 \times).

strong pieces of evidence that ROS such as superoxide, hydrogen peroxide, hydroxyl radical and hypochlorous acid are involved as mediators of experimental and human IBD. Also, nitric oxide and peroxynitrite have been suggested as potential mediators of colitis induction [12, 13]. Recently, we reported antioxidative properties of *c*-phycoyanin in various *in vitro* and *in vivo* experimental models [5]. These results indicate that phycoyanin is able to scavenge hydroxyl and alcoxyl radicals as well as it inhibits liver microsomal lipid peroxidation and the chemiluminescence response of human PMNL activated by zymosan. Furthermore, phycoyanin reduced oedema index in glucose oxidase-induced inflammation in mouse paw, an effect that is mediated by hydrogen peroxide and hydroxyl radical [5].

Taking into account these findings and the results of others [14] it is conceivable that phycoyanin exerts its anti-inflammatory effect in colitis at least in part by scavenging ROS. The beneficial effect of 5-ASA in IBD has also been ascribed to its potent antioxidative and free radical scavenger properties [15].

Other potential mediators that can be implicated in the anti-colitis effect of phycoyanin are leukotrienes, especially LTB₄ which has been shown to increase in the inflamed colonic mucosa of IBD [1] and experimental colitis [16]. This mediator has potent chemotactic properties on neutrophils.

Recently, we also found the anti-inflammatory activity of phycoyanin and in the same range of doses in carrageenan-induced rat paw oedema, TPA-induced mouse ear oedema and cotton pellet granuloma in rats [17]. In these experimental models of inflammation as well as in experimental colitis, metabolites of arachidonic acid play an important role. Currently, research is in progress in our laboratory in order to elucidate whether or not the inhibition of arachidonic acid metabolism is involved in the mode of action of phycoyanin as an anti-inflammatory agent.

Phycoyanin is a constituent and the most abundant pigment in blue-green microalgae and accounts for more than 20% of algae by dry wt. [18].

Taking into account that these microalgae are used as dietary supplements in many countries, our results on the effects of phycoyanin in this experimental model of colitis provide evidence and may be relevant for the potential use of these microalgae as feed supplement in patients with IBD. However, further preclinical and clinical studies are required in order to confirm it

ACKNOWLEDGEMENTS

The authors thank Ms. Enis Rojas, Ms. Amelia Capote and Ms. Maria Elena Ramos for skilful technical assistance.

REFERENCES

1. Fretland DJ, Djuric SW, Gaginella TS. Eicosanoids and inflammatory bowel disease: regulation and prospects for therapy. *Prost Leukotr Ess Fatty Acids* 1990; **41**: 215–33.
2. Grisham MB. Role of reactive oxygen metabolites in inflammatory bowel disease. *Curr Opin Gastroenterol* 1993; **9**: 971–80.
3. Lih-Brody L, Powell SR, Collier KP, Reddy GM, Cerchia R, Kahn E, Weissman GS, Katz S, Floyd RA, McKinley MJ, Fisher S, Mullin GE. Increased oxidative stress and decreased antioxidant defences in mucosa of inflammatory bowel disease. *Dig Dis Sci* 1996; **41**: 2078–86.
4. Sedghi S, Fields J.Z, Klamut M, Urban G, Durkin M, Winship D, Fretland D, Olyae M, Keshavarzian A. Increased production of luminol enhanced chemiluminescence by the inflamed colonic mucosa in patients with ulcerative colitis. *Gut* 1993; **34**: 1191–7.
5. Romay Ch, Armesto J, Ramirez D, González R, Ledon N, García I. Antioxidant and anti-inflammatory properties of C-phycoyanin from blue-green algae. *Inflamm Res* 1998; **47**: 36–41.
6. Benitez F, Travieso L, Dupeiron R. Method for phycoyanin obtainment from microalgae. Cuban patent pending RPI: 111/97.
7. Berns DS, MacColl R. Phycoyanin in physical-chemical studies. *Chem Rev* 1989; **89**: 807–25.
8. Fretland D, Widomski D, Anglin C, Walsh R, Levin S, Gasielki TA, Collins PW. Mucosal protective activity of prostaglandin analogs in rodent colonic inflammation. *Inflammation* 1992; **16**: 623–9.
9. Bradley PP, Priebe DA, Christensen RD, Rothstein G. Measurement of cutaneous inflammation: estimation of neutrophils content with an enzyme marker. *J Invest Dermatol* 1982; **78**: 206–9.
10. Fabia R, Rajab AR, Willen R, Marklunt S, Andersson R. The role of transient mucosal ischemia in acetic acid-induced colitis in the rat. *J Surg Res* 1996; **63**: 406–12.
11. Higa A, Eto T, Nawa Y. Evaluation of the role of neutrophils in the pathogenesis of acetic acid-induced colitis in mice. *Scand. J Gastroenterol* 1997; **32**: 564–8.
12. Rachmilewitz D, Karmeli F, Okon E, Bursztyn M. Experimental colitis is ameliorated by inhibition of nitric oxide synthase activity. *Gut* 1995; **37**: 247–55.
13. Rachmilewitz D, Stamler JS, Karmeli F, Mullins ME, Singel DJ, Loscalzo J, Xavier RJ, Podolsky DK. Peroxynitrite-induced rat colitis. A new model of colonic inflammation. *Gastroenterology* 1993; **105**: 1681–8.
14. Conner EM, Grisham MB. Inflammation, free radicals and antioxidants. *Nutrition* 1996; **12**: 274–7.
15. Ahnfelt-Ronne I, Haagen Nielsen O. The anti-inflammatory moiety of sulfasalazine, 5-aminosalicylic acid, is a radical scavenger. *Agents Actions* 1987; **21**: 191–4.
16. Sharon P, Stenson WF. Metabolism of arachidonic acid in acetic acid colitis in rats: similarity to human inflammatory bowel disease. *Gastroenterology* 1985; **88**: 55–63.
17. Romay Ch, Ledón N, González R. Further studies on anti-inflammatory activity of phycoyanin in some animal models of inflammation. *Inflamm Res* 1998; **47**: 334–8.
18. Henrikson R. Microalgae *Spirulina*. 2nd ed. Barcelona: Urano. 1994:39–59.